

# Pathology and Staging


## Patient information

### Pathology

A pathologist is a specialist doctor who examines tissue under a microscope to detect diseased cells. If you or your doctor find a suspicious looking spot or lump, a biopsy can determine whether there are melanoma cells present. Once a biopsy has been taken, the sample will be sent to a pathologist for examination.

Common biopsy procedures include:

- **Excision biopsy** where a scalpel is used to remove the entire affected area and often some healthy tissue for examination
- **Punch biopsy** involving the removal of a circular area of skin with an instrument known as a punch
- **Incision biopsy** where a scalpel is used to remove a portion of the affected tissue for examination
- **Shave biopsy** where a superficial area of the lesion is taken off, often with a razor-type blade
- **Fine needle biopsy** where a needle similar to that used for blood collection is used to capture a sample of cells.



When the pathologist receives your tissue, they carefully inspect it and select areas for detailed examination under a microscope. The tissue is then set in paraffin wax (creating a block), sliced thinly and the sections are stained with dyes so that they can be seen under a microscope at high magnification. The unused tissue remaining in the paraffin wax is stored by the pathology laboratory. Further samples can be taken from the same block if more tests are needed. Following examination, the pathologist will write up their findings in a pathology report. This report will be sent to your doctor so he or she can discuss the results with you.

#### How long do pathology reports take?

A complete pathology report can take up to two weeks to prepare. This report contains information that will guide your treatment.

#### How do I get a copy of my pathology reports?

If, at any time, you would like a copy of your pathology reports you can request one from your doctors.

# Understanding pathology reports

Your pathology report will have a detailed description of your tissue sample and may look similar to the example shown below.

<b>The Melanoma Hospital</b>		<b>Patient name:</b> CLAYTON, Amelia <b>DOB/Sex:</b> 28/09/1967, M <b>Requested by:</b> Dr Maurice, Karl <b>Requested on:</b> 09/02/2021 <b>Specimen received:</b> 12/01/2021
<b>SAMPLE PATHOLOGY REPORT</b>		
<b>CLINICAL DETAILS</b>		
Changing lesion right back		
<b>MACROSCOPIC</b>		
Oval piece of skin measuring 30 x 50 mm		
<b>MICROSCOPIC REPORT</b>		
<b>Specimen type:</b> Excision		
<b>Site:</b> Right back		
<b>Diagnosis:</b> Melanoma		
<b>Classification/Main pattern:</b> Nodular		
<b>Thickness:</b> Breslow 2.6 mm		
<b>Clark level:</b> IV		
<b>Ulceration:</b> Present		
<b>Dermal mitoses:</b> 5 per mm <sup>2</sup>		
<b>SUMMARY</b>		
Skin right back, excision, NODULAR MELANOMA		

Your doctor will explain what your results mean and how this will determine further procedures or treatment recommendations. The terms typically used in pathology reports are explained on the next few pages and will help you to understand what your results mean. If you have further questions, talk to your doctor.

## Macroscopic description

This is a description of what the pathologist sees when looking at your sample with the naked eye. The specimen type refers to the type of sample that was taken from you, whether a shave, punch, incision, excision or fine needle biopsy. Site is the area on your body where the biopsy came from. This part of the report may describe the size of the sample, and the size and appearance of any lesion within it.

## Microscopic description

This is a description of what the pathologist observes from looking under the microscope and provides more technical and diagnostic information.

## Diagnosis

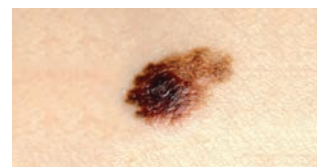Melanoma. This diagnosis will also usually be confirmed in the summary of the report.

## Type of melanoma/classification

There are different types of melanoma and your pathology report will outline how your melanoma is classified.

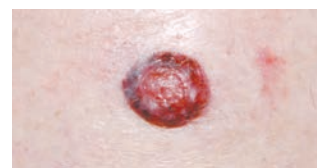- **Superficial spreading melanoma**

This is the most common type of melanoma making up about 50% of all melanomas diagnosed. This melanoma usually appears as a dark spot with irregular borders that spreads across the skin.



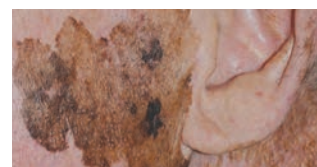- **Nodular melanoma**

Nodular is one of the most rapidly growing types of melanoma. It appears as a raised lump or 'nodule' and can be brown, black, pink or red in colouring, or have no colour at all. About 15% of all melanomas are nodular.



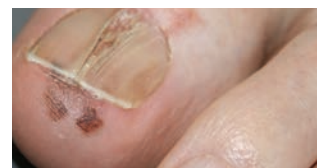- **Lentigo maligna melanoma**

Lentigo maligna melanomas begin as large freckles. They are commonly found in older people, often in areas that have received a lot of sun exposure such as the face, head, neck and upper body. This type of melanoma makes up 10% of all melanomas.



- **Acral lentiginous melanoma**

Acral is a rare type of melanoma that tends to grow on the palms of hands, soles of the feet or under the nails (subungual). It accounts for about 3% of all melanomas.



Other, less common types of melanoma include desmoplastic and naevoid melanoma. Mucosal melanomas can be found in tissues in the respiratory, digestive, and reproductive tracts. Uveal (ocular) melanomas develop in the eye.

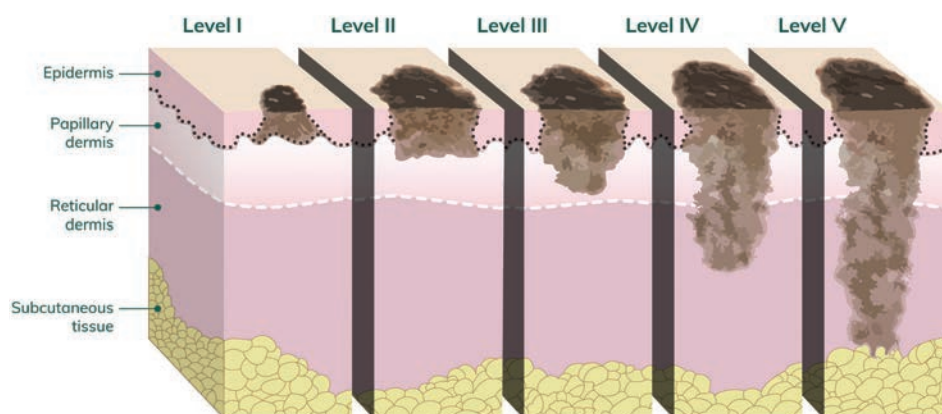
## Breslow thickness

This is the depth of your melanoma in millimetres and is used along with other features to stage the melanoma. Thinner melanomas have a better prognosis.

Thickness	Description
Less than 1 mm	Thin melanoma
1–4 mm	Intermediate thickness melanoma
Greater than 4 mm	Thick melanoma

## Clark level

Your pathology report may also show a Clark level of invasion. This is a number that ranges from 1–5 (written in Roman numerals I–V) to describe how deeply the cancer has penetrated the skin. Clark level 5 (V) is the deepest level of invasion.



## Ulceration

Ulceration is the breakdown of the top layer of skin over the melanoma. The presence or absence of ulceration is used to help determine the stage of melanoma. The presence of ulceration indicates a more rapidly growing melanoma.

## Dermal mitoses

This describes how quickly the melanoma cells are dividing. Higher mitotic rates (e.g. greater than 5 per mm<sup>2</sup>) indicate faster growing melanoma and are associated with a worse prognosis.

## Surgical margin

The report may describe the presence or absence of melanoma cells at the edges or deepest part of the sample (surgical margins). If these margins are positive (melanoma cells are present) more surgery may be needed.

## Lymph node pathology report

If you have had a sentinel node biopsy, or you have had lymph nodes removed during surgery, the pathology report you receive after these procedures will record information about the number of nodes retrieved, the number of nodes containing melanoma and whether the melanoma has breached the node (called extra-nodal spread). The greater the number of lymph nodes containing melanoma, the poorer the prognosis. Extra-nodal spread is also associated with a poorer prognosis.

# Staging melanoma

Staging a melanoma provides a description of how widespread the cancer is. Characteristics described in your pathology report including Breslow thickness, ulceration, mitoses and the involvement of lymph nodes or spread to other organs determine the stage of your melanoma. This in turn, helps guide the treatment approach your doctor will recommend for you.

## Stages of melanoma and likely treatment options

Stage	What does this mean?	Likely course of action
<b>Stage 0 (in-situ)</b>	Melanoma is confined to the cells in the top layer (epidermis) of the skin. The melanoma has not invaded deeper layers (dermis) where there are lymphatic and blood vessels to spread to.	<ul style="list-style-type: none"><li>– Surgical removal (wide local excision)</li></ul>
<b>Stage I</b>	Melanoma can be up to 2mm in thickness without ulceration; or up to 1mm in thickness with ulceration.	<ul style="list-style-type: none"><li>– Surgical removal (wide local excision)</li><li>– Sentinel node biopsy may be considered to rule out spread of melanoma to lymph nodes</li></ul>
<b>Stage II</b>	Melanoma can be over 2mm in thickness without ulceration; or 1 to >4mm in thickness with ulceration and no lymph node spread.	<ul style="list-style-type: none"><li>– Surgical removal (wide local excision)</li><li>– Sentinel node biopsy may be considered to rule out spread of melanoma to lymph nodes</li><li>– Consideration of additional drug (systemic) therapy treatment after surgery</li></ul>
<b>Stage III</b>	Melanoma has spread to local lymph nodes or nearby tissues (in-transit disease).	<ul style="list-style-type: none"><li>– Surgical removal (wide local excision) for in-transit disease</li><li>– Consideration of lymph node dissection (removal of all lymph nodes in the affected region)</li><li>– Consideration of additional treatments before or after surgery, such as radiation therapy or drug (systemic) therapies</li></ul>
<b>Stage IV</b>	Melanoma has spread (metastasised) to distant lymph nodes or to distant parts of the body (e.g. lung, liver, brain, bone).	<ul style="list-style-type: none"><li>– Drug (systemic) therapy may be used</li><li>– Radiation therapy or surgery may also be considered</li></ul>

# Molecular pathology testing and mutations in melanoma

If you have Stage III or Stage IV melanoma, your doctor may talk to you about a BRAF test or mutation testing that looks for changes (mutations) in the DNA code of your melanoma.

BRAF (pronounced B-Raf) is a protein found in all cells and is part of a signalling pathway that encourages healthy cell growth. Approximately 40% of melanomas are found to have a BRAF mutation. The abnormal (mutated) BRAF causes the melanoma cells to grow in an uncontrolled way. People who have this mutation in their melanoma may benefit from drugs that specifically target abnormal BRAF.

The test itself can often be conducted using the tissue that was removed during your previous surgery so often does not require an additional procedure.

## What happens to my tissue?

After surgery to remove the melanoma, a small part of the tissue removed is examined by the pathologist to prepare the pathology report. Some of the remainder of the tissue is stored in wax blocks by the pathology department. It is possible to do multiple tests using this same block of tissue.

Patients of Melanoma Institute Australia are invited to become donors to the Biospecimen Bank. The Biospecimen Bank is a collection of samples from body organs or fluids which are stored for current and future research purposes. This research is vital for improving the care of current and future patients with melanoma. If you agree to be a donor, we will take a small sample of tissue that is not required for pathology and store this in the Bank.

## Further reading

You may like to read our other patient information brochures on [melanoma.org.au](http://melanoma.org.au), including:

- Biospecimen Bank

**Please note: The information in this brochure is of a general nature and should not replace the advice of healthcare professionals. All care has been taken to ensure the information presented here is accurate at the time of publishing (July 2021).**

Melanoma Institute Australia  
The Poche Centre  
Cammeraygal Land  
40 Rocklands Road  
Wollstonecraft NSW 2065

**P** 02 9911 7200  
**F** 02 9954 9290  
**E** [info@melanoma.org.au](mailto:info@melanoma.org.au)  
**W** [melanoma.org.au](http://melanoma.org.au)

  
Melanoma  
Institute Australia